



Studying the influence of Solcoseryl drug and vitamin C on the inflammatory reaction and proliferation of fibroblastic cells in the field of polypropylene endoprosthesis implantation

Viktor A. Lazarenko¹, Sergey V. Ivanov¹, Tatyana A. Pankrusheva¹, Ilya S. Ivanov¹, Evgeny G. Ob'edkov¹, Galina N. Goryainova¹, Lyubov A. Kopteva¹, Marina S. Chekmareva¹, Inna A. Ivanova¹, Natalya Ju. Ob'edkova¹

¹ Kursk State Medical University, 3 K. Marx St., Kursk 305041, Russia

Corresponding author: Evgeny G. Ob'edkov (cinnamonkla@yandex.ru)

Academic editor: Oleg Gudyrev ♦ **Received** 1 July 2021 ♦ **Accepted** 18 September 2021 ♦ **Published** 29 September 2021

Citation: Lazarenko VA, Ivanov SV, Pankrusheva TA, Ivanov IS, Ob'edkov EG, Goryainova GN, Kopteva LA, Chekmareva MS, Ivanova IA, Ob'edkova NJu (2021) Studying the influence of solcoseryl drug and vitamin c on the inflammatory reaction and proliferation of fibroblastic cells in the field of polypropylene endoprosthesis implantation. *Research Results in Pharmacology* 7(3): 83–91. <https://doi.org/10.3897/rrpharmacology.7.70931>

Abstract

Introduction: Applying a coating on hernia endoprosthesis prevents recurrent anterior abdominal wall hernias, reduces inflammatory response and stimulates reparative processes in the area of its implantation. The aim of investigation was to study the effect of Solcoseryl and **Vitamin C** in a collagen-stimulating coating of hernioendoprosthesis on a morphological picture in anterior abdominal wall plastic surgery.

Materials and methods: The study was performed on 180 laboratory mice divided into three groups of 60 animals each: the first group animals were implanted with polypropylene endoprostheses without a collagen-stimulating coating, the second group animals – polypropylene endoprostheses with a collagen-stimulating coating with **Vitamin C**, and the third group animals – polypropylene endoprostheses with a collagen-stimulating coating with Solcoseryl. The laboratory animals were withdrawn from the experiment on the 10th, 30th, 60th, and 90th days. The excised sections of the abdominal wall were stained with G+E to determine the nature of inflammation and the number of cell elements.

Results and discussion: When using endoprostheses with a collagen-stimulating coating, the stages of inflammatory process proceeded more quickly, which was confirmed by a reliable ($p \leq 0.05$) decrease in the number of neutrophils, macrophages and lymphocytes at all stages of the study. By the 90th day of the experiment, the number of fibroblasts in the control group was by 22.64% less than in the study groups with a coating.

Conclusion: A cytological and histological analysis in the control group determined a consistent decrease in an exudative phase of inflammatory reaction. When using endoprosthesis with coatings, its acceleration and lower intensity was noted throughout the study. In the group with Solcoseryl, the formation of a dense connective capsule around the endoprosthesis indicates its quality and better adaptation of the endoprosthesis in body tissues.

Keywords

cytological study, endoprosthesis, hemodialysis, inflammation, Solcoseryl, ventral hernia, **Vitamin C**.

Introduction

Hernias are the second most frequent cause of operations in general surgery. Postoperative ventral hernias (POVH) have become most common, which can be explained by an impaired ability of the abdominal wall to counteract intraperitoneal pressure after surgical interventions (Sukovatykh et al. 2016). Despite a wide choice of materials for hernial defect plastic surgery and methods of treating those defects, there are difficulties in preventing recurrence and complications of ventral hernias (Hamidian Jahromi et al. 2020). To achieve this goal, it is necessary to create a hernia endoprosthesis that affects both the wound process and the process of collagen metabolism (Sukovatykh et al. 2016; Ermolov et al. 2018). During implantation of a hernia endoprosthesis, wound healing proceeds successively through all the stages of wound process development. However, a response of tissues to the endoprosthesis as a foreign body can provoke some repair difficulties, for example, extension of the exudative phase of inflammation and increased exudation (Ivanov et al. 2020).

There are various ways to influence the regeneration process: wound drainage, the use of hypertensive solutions, ointments, enzymotherapy, antiseptics, physical treatments, and laser. The idea of an internal effect on wound healing is associated with the application of various coatings to endoprostheses, such as antibiotics, hormones, alginates, chitosan, gelatin, fibrin, collagen, etc. (Guessasma et al. 2017; Laronda et al. 2017; Graf et al. 2018; Aleksandrushkina et al. 2019; Ballard et al. 2019; Stepenko et al. 2019). Today the use of endoprostheses with coatings based on a substance that influences the collagen formation process and accelerates the wound healing process is most promising (Ivanov et al. 2020).

Solcoseryl is a drug that allows correcting the collagen formation and preventing complications and recurrences of postoperative ventral hernias. Solcoseryl is a deproteinized hemodialysate that is obtained from blood of vealers. This drug belongs to several pharmacological groups: antihypoxants and antioxidants, angioprotectors and microcirculation correctors, regenerants and reparants. Solcoseryl contains a large number of active substances that supply cells with high-energy phosphates by improving glucose transport, aerobic glycolysis and oxidative phosphorylation, reduce degenerative processes in tissues and improve reparative ones, and therefore can correct various phases of wound repair and affect collagen formation (Lazarenko et al. 2016; Ob'edkov et al. 2019; Ivanov et al. 2020; Register of Medicines of Russia 2021a, b). The drug has a systemic effect when injected intravenously or intramuscularly and can be used topically as ointment or gel, the dosage depends on a nosological form of the disease.

Ascorbic acid is a water-soluble vitamin that cannot accumulate in the body. The drug has antioxidant and metabolic effects, replenishes **vitamin C** deficiency and regulates redox processes. **Vitamin C** affects the synthesis of DNA, intracellular collagen, lipids and proteins, oxidative phosphorylation, carbohydrate metabolism, has antioxidant properties due to the regulation of H⁺ ion transport,

regulates immunological reactions (activates synthesis of antibodies, C3 component of the complement, interferon), promotes phagocytosis, increases body's resistance to infections, has anti-inflammatory and anti-allergic effects, inhibits release and accelerates the degradation of histamine, inhibits the formation of prostaglandins and other inflammatory mediators and anaphylaxis, reduces the need for **vitamins B₁, B₂, A, E, folic acid**, and **pantothenic acid**. Such properties of **ascorbic acid** allow it to influence the process of collagen formation, accelerating the process of wound healing, shortening the exudative phase of inflammation, stimulating the maturation of connective tissue, normalizing the ratio of collagen types I and III and accelerating the formation of a postoperative scar (Lazarenko et al. 2019; Register of Medicines of Russia 2021a, b). The maximum absorption of the drug (70%) is achieved at a dosage of 200 mg. **Vitamin C** can be administered orally, intramuscularly, intravenously, intravaginally, the dosage depending on the nature and course of the disease.

Thus, the use of collagen-stimulating coatings will allow influencing repair processes topically, reducing exudation, increasing proliferation and formation of mature collagen fibers (Tappa et al. 2017; Tappa et al. 2018; Ivanov et al. 2020).

Aim of the study: to study a morphological picture in the field of implantation of a polypropylene endoprosthesis for anterior abdominal wall plasty depending on application of a collagen-stimulating coating.

Materials and methods

Animals

Our experimental study was carried out on 180 white laboratory male mice of Wistar breed. All the animals had undergone complete quarantine in the experimental biological clinic of Kursk State Medical University before the experiment. The study was carried out in full compliance with the Council of Europe's Convention for the Protection of Vertebrate Animals used for Experimental and other Scientific Purposes (Strasbourg, 1986). In addition, we had adhered to all the Council Directives 86/609/EEC (November 24, 1986), such as the rules, laws and administrative orders of the participating countries regarding the protection of animals used in the experimental studies.

Experiment design

The animals were divided into three groups with 60 mice per each one before starting the experiment. The first group of animals (control group) was implanted with a polypropylene endoprosthesis (Esfil, Lintex, Russia) without application of a collagen-stimulating coating. We implanted an endoprosthesis coated with solution of **Vitamin C** to the animals of the second group. As for the third group of mice, we implanted an endoprosthesis coated with Solcoseryl solution.

Test substance

The faculty members of the Department of Pharmaceutical Technology (Kursk State Medical University) developed the composition of collagen-stimulating coatings and the method of their application on the endoprosthesis, based on the results of previous studies (the RF Patent for invention No. 2740132 / 12.01.2021. Obedkov EG, Ivanov I.S., Ivanova IA, Goryainova GN, Chekmareva MS, Pankrusheva TA Method of applying a collagen-stimulating coating on the endoprosthesis). The composition of the coating included such components as **Vitamin C** and Solcoseryl. We used **methylcellulose** as a thickener, proportion was 2.0 grams per 98 grams of the drug. Method of manufacture: due to an aseptic technique, 2.0 grams of **methylcellulose** was dissolved in 98 ml of solution for injection in a sterile container and stirred until complete dissolution and obtaining a homogeneous mass. The prepared solution was placed in a refrigerator at a temperature of 4 °C for 24 hours. After removing from the refrigerating chamber, the prepared mass was homogenized, poured into sterile Petri dishes and left for 2 hours in a locker at a temperature of 20 °C for aerating. After getting the Petri dishes out of the locker, we immersed endoprostheses for anterior abdominal wall into the prepared solution for 60 minutes. Then the endoprostheses were removed and dried in the thermostat at temperature of 20 °C for 5 hours in order to immobilize the coating. After sterilization, the endoprostheses were implanted to the experimental animals.

The experiment was carried out on the basis of the Research Institute of Ecological Medicine of Kursk State Medical University in the conditions of the operating unit. Surgical interventions were conducted in aseptic conditions. The animals were placed in an isolated chamber with ether before implantation of an endoprosthesis; anesthesia was given through an “ether mask” during surgery. The shaved area of the abdominal wall was treated with a 70% ethyl alcohol solution at the beginning of the operation. A 15-mm long skin incision was made along the anterolateral surface; later, using a clamp, the skin and subcutaneous fat were separated from the underlying muscles of the abdominal wall by blunt dissection. An endoprosthesis with a size of 10*5 mm was placed into a formed cavity, such an arrangement simulating on-lay plasty. After implantation, the postoperative wound was sutured with 4 separate interrupted sutures. The animals were removed from the experiment on the 10th, 30th, 60th, and 90th days, such terms being chosen due to the stages of wound processes.

Research material

The animals were removed from the experiment with an overdose of ether; then, the abdominal wall section comprising the skin, muscles and the endoprosthesis was excised. The resulting fragment sized of 10*10 mm was placed in a test tube with a 10% formalin solution. The

material was fixed in paraffin blocks, from which sections 4–5 µm thick were made. These sections were stained using the hemotoxylin+eosin (H+E) technique to determine the nature and amount of cellular elements. The cell elements were counted using a light microscope, the magnification of the eyepiece was x10, the magnification of the objectives was x25 and x40. The eyepiece had a 1*1 mm insert to limit the field of view. Histological photographs of the preparations were obtained using an Altami 3 Mpx digital eyepiece camera. Investigation of the histological sections included a study of 10 “standard fields of view” in each of them.

Statistical processing

We counted such cellular elements as fibroblasts, lymphocytes, macrophages, and neutrophils when determining the nature of the morphometric picture at the site of endoprosthetics. The calculation of these elements made it possible to define the nature of inflammation and its intensity, which characterized the effect of the applied coating on the process of inflammation and regeneration. A statistical analysis included the calculation of the mean quantitative indicators (M), standard deviation (m), Pearson’s correlation coefficient (r), Student’s test of reliability, and Mann-Whitney test for two independent groups.

Results and discussion

The features of the cell composition at the site of Esfil endoprosthesis implantation without application of a collagen-stimulating coating are shown in Table 1.

Table 1. Cell composition at site of Esfil endoprosthesis implantation without applied collagen-stimulating coating

| Cells, % Day | Fibroblasts, fibrocytes | Macrophages | Lymphocytes | Neutrophils |
|-----------------|----------------------------|------------------------|---------------------------|---------------------------|
| 10 | 60.1 ± 1.14 ^b | 6.0 ± 0.6 ^b | 17.5 ± 1.07 ^b | 18.4 ± 1.62 |
| 30 | 64.2 ± 1.1 ^{ab} | 5.8 ± 0.73 | 15.5 ± 0.64 ^{ab} | 14.5 ± 0.75 ^{ab} |
| 60 | 69.9 ± 1.44 ^{ab} | 5.8 ± 0.47 | 16.0 ± 0.72 ^b | 8.3 ± 0.39 ^{ab} |
| 90 | 71.7 ± 1.49 ^b | 5.5 ± 0.55 | 16.6 ± 0.54 ^b | 6.2 ± 0.6 ^{ab} |

Note: ^a – the validity criterion $p \leq 0.05$ when compared with the previous term when comparing the same cell type in the first group, ^b – the validity criterion $p \leq 0.05$ when compared with the same period of time of the same cell type between the groups.

On the 10th day of the experiment, a significant amount of amorphous connective tissue substance is observed in the area of implantation of the endoprosthesis (Fig. 1A). A cytological analysis shows a predominance of fibroblastic cells, mainly represented by fibroblasts (60.1%). The exudative stage of inflammation is moderately pronounced (neutrophils 18.4%, and lymphocytes 17.5%). Fibroblasts form the main substance of connective tissue; thin connective fibers appear in the walls of meshes and around the threads of the endoprosthesis. The resulting connective tissue gradually fills the space between endoprosthesis fibers.

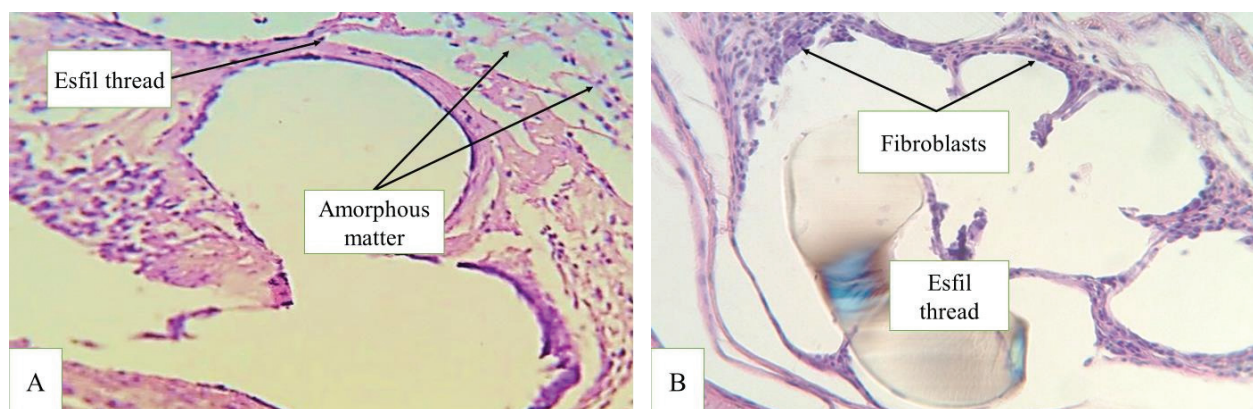


Figure 1. Microscopic picture at the site of Esfil endoprosthesis on the 10th day (A) and 30th day (B). **Note:** staining H+E. Light microscopy. X250.

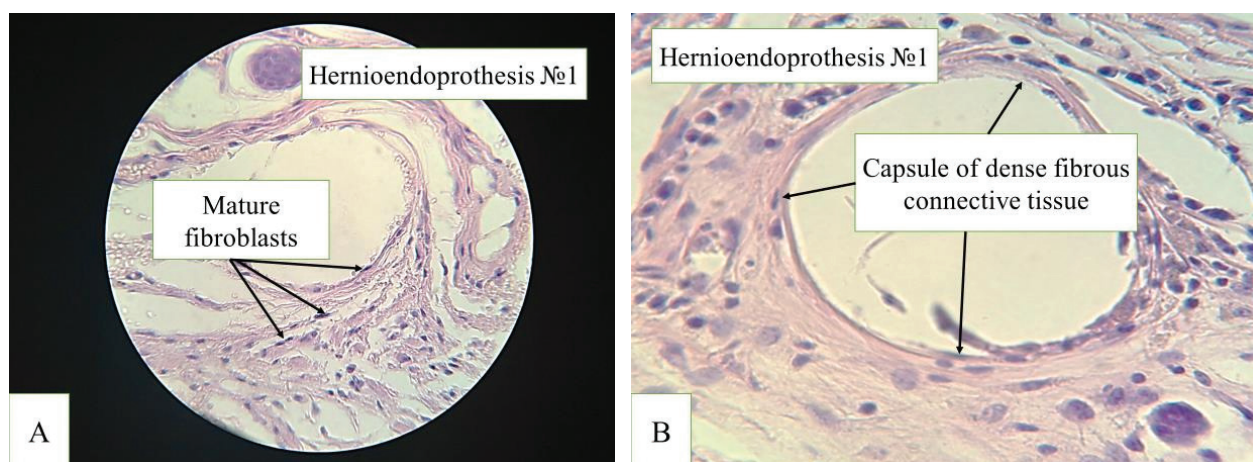


Figure 2. Microscopic picture at the site of Esfil endoprosthesis on the 60th day (A) and 90th day (B). **Note:** staining H+E. Light microscopy. X400.

By the 30th day, the volume of neutrophils and lymphocytes significantly ($p \leq 0.05$) decreases (14.5% and 15.5%, respectively), while the number of mature fibroblasts increases (64.2%). The exudative phase of inflammation fades; the processes of proliferation and wound healing at the site of implantation of the endoprosthesis are intensified. A histological analysis identifies the forming connective tissue fibers and fibrocytes located mainly in the mesh walls (Fig. 1B). Sporadic focal inflammatory cell infiltrates are noted, as well as clusters of cells of foreign bodies. The spaces between the cells are filled with loose connective tissue.

By the 60th day, there are predominantly mature fibroblasts (69.9%) in the cellular composition around the endoprosthesis threads, the volume of which increases significantly ($p \leq 0.05$) compared to the previous study terms; the number of neutrophils (8.3%) also significantly ($p \leq 0.05$) decreases; the number of giant cells of foreign bodies decreases (Fig. 2A). Between the threads of the endoprosthesis, there is loose connective tissue with a significant number of fibroblasts of various degrees of maturity, which indicates the ongoing organization process at the site of implantation of the endoprosthesis. The densest and most mature

fibers are located in the outer layer of the paraprosthetic capsule.

By the 90th day, the dynamics of cell composition keep changing towards a decrease in the volume of inflammatory structures and an increase in the volume of connective tissue structures (Fig. 2B). Inflammatory cell elements in the region of the paraprosthetic capsule are represented by neutrophils (6.2%); the volume of lymphocytes does not significantly ($p \leq 0.05$) change (16.6%), which, along with the presence of giant cells of foreign bodies, indicates a persistent response to the endoprosthesis. The histological pattern at the site of the implanted endoprosthesis on the 90th day is characterized by the presence of dense fibrous connective tissue and a small number of fibrocytes located in the walls of the meshes. Connective tissue fibers are denser than those at the previous stages; some of them are homogeneous. There are focal clusters of fibroblasts in the walls of paraprosthetic capsules ingrowing into the inside fibrous septic meshes, which indicates the ongoing formation of the connective tissue framework of the endoprosthesis threads. Around the paraprosthetic capsules, the connective tissue is more fibrous and contains a larger quantity of fibrocytes, fibroblasts, and newly formed vessels.

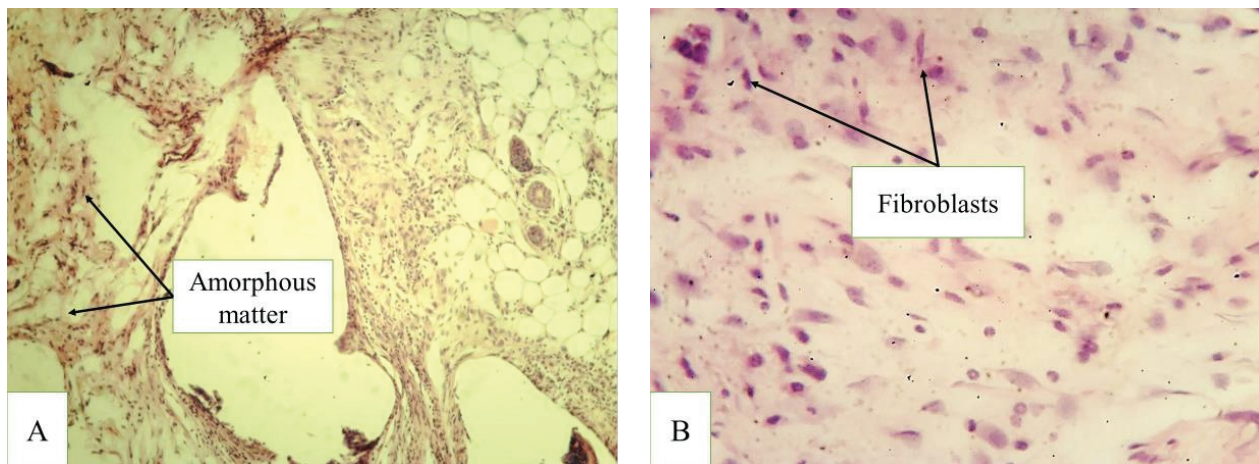


Figure 3. Microscopic picture at the side of Esphil endoprosthesis with a coating containing **Vitamin C** on the 10th day (A) and 30th day (B). **Note:** staining H+E. Light microscopy. X100 (A) and X400 (B).

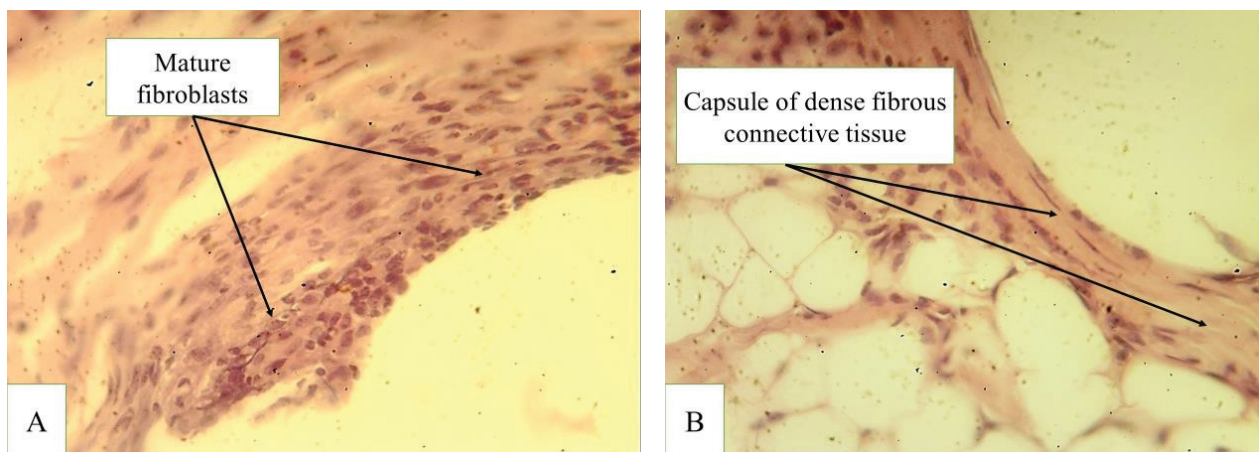


Figure 4. Microscopic picture at the site of Esphil endoprosthesis with a coating containing **Vitamin C** on the 10th day (A) and 30th day (B). **Note:** staining H+E. Light microscopy. X400.

Use of Vitamin-C coating

On the 10th day after the endoprosthesis operation and using a coating containing **Vitamin C**, some forming capsules with smooth walls, infiltrated with inflammatory cell elements, are found (Fig. 3A), with fibroblasts being the predominant cell elements. In the walls of the capsules, there are small focal hemorrhages and clusters of siderophages. Small clusters of eosinophils, single multi-nuclear macrophages (cells of foreign bodies), mast and plasma cells are detected on the inside of the capsule walls. Some capsules are not isolated, combined into large meshes containing several threads of the endoprosthesis.

By the 30th day in this group, the capsule walls are represented by loose connective tissue, the connective fibers are occasionally split. Inflammatory cell infiltrate is scarce, represented by macrophages, single eosinophils and mast cells. The predominant cell elements are fibroblasts (73.25%) (Fig. 3B). Among inflammatory cell elements, the proportion of macrophages and lymphocytes increases, whereas the number of neutrophils decreases

by half. There are many fibrocytes in the inner layers of the capsule walls, with single mast cells and multi-nuclear cells of foreign bodies. By the 30th day, dense isomorphic connective fibers are detected in the capsule walls; red blood cell clusters are not detected, with focal clusters of siderophages remaining in their place.

By the 60th day, capsules are fully formed (Fig. 4A). The Esfil endoprosthesis threads are separated from each other by fibrous bridles – septa between the capsule walls. Some bridles are very thin, with small areas of fissures and ruptures. In the walls of the capsules, there is isomorphic fibrous connective tissue, whereas between the capsules, connective tissue is mature. The cellular composition is even more dominated by fibroblasts (82.85%). The downward trend in the neutrophil ratio persists and reaches 4.9% (Table 2). Small focal clusters of macrophages, single lymphocytes and neutrophils are present in the inner layer of the capsules in direct contact with the threads of the endoprosthesis. In the connective tissue between the capsules, the newly formed vessels form “bags”; hyperemia is observed.

Table 2. Cell composition at the site of an Esfil endoprosthesis implantation with coating containing Vitamin C

| Cells, % Day | Fibroblasts, fibrocytes | Macrophages | Lymphocytes | Neutrophils |
|-----------------|----------------------------|----------------------------|-------------|---------------------------|
| 10 | 66.89 ± 2.34 | 7.53 ± 0.74 | 4.45 ± 0.61 | 21.13 ± 2.03 |
| 30 | 73.25 ± 1.9 ^{ab} | 10.84 ± 0.87 ^{ab} | 6.13 ± 1.09 | 9.78 ± 0.78 ^{ab} |
| 60 | 82.85 ± 1.91 ^{ab} | 4.66 ± 0.74 ^a | 7.60 ± 1.21 | 4.89 ± 0.92 ^{ab} |
| 90 | 86.63 ± 1.89 ^b | 4.51 ± 0.81 | 6.29 ± 0.63 | 2.57 ± 0.44 ^{ab} |

Note: ^a – the validity criterion $p \leq 0.05$ when compared with the previous term when comparing the same cell type in the first group, ^b – the validity criterion $p \leq 0.05$ when compared with the same period of time of the same cell type between the groups.

By the 90th day, the walls of the capsules are thick, made of dense isomorphic fibrous connective tissue (Fig. 4B). The cell composition is represented mainly by fibroblasts (86.63%); inflammatory cell elements are small in number; the proportion of macrophages and lymphocytes increased slightly, whereas the number of neutrophils halved to 2.57% (Table 2).

Use of Solcoseryl coating

On the 10th day after endoprosthesis replacement, when using a Solcoseryl coating, forming capsules with smooth walls, infiltrated with inflammatory cell elements, are found. The capsule walls around the endoprosthesis threads are represented by immature cell-rich connective tissue. The forming connective fibers are thin; there are foci with split fibers. Around the capsules, loose connective tissue is rich in cells and vessels. On the inner surface of the capsules, there are inflammatory cell infiltrates, in which half of the cell composition is represented by neutrophils (15.98%), their proportion is significantly ($p \leq 0.05$) lower than in the group where no coating was applied (Table 3). The proportion of macrophages is higher (8.17%) than that of lymphocytes (5.71%). At the same time, the number of fibroblasts is significantly ($p \leq 0.05$) higher (71.14%) compared to the no-coating group (60.1%). In addition, mast cells are determined. The walls of the capsules are loosely connected to the surrounding

Table 3. Cell composition at site of Esfil endoprosthesis with solcoseryl coating

| Cells, % Day | Fibroblasts, fibrocytes | Macrophages | Lymphocytes | Neutrophils |
|-----------------|----------------------------|---------------------------|---------------------------|---------------------------|
| 10 | 71.14 ± 2.97 ^b | 8.17 ± 0.94 | 5.71 ± 0.78 ^b | 15.98 ± 1.13 |
| 30 | 79.98 ± 2.54 ^{ab} | 5.88 ± 0.87 ^a | 8.52 ± 1.27 ^{ab} | 5.61 ± 0.53 ^{ab} |
| 60 | 87.99 ± 1.79 ^{ab} | 3.36 ± 0.61 ^{ab} | 6.09 ± 1.13 ^b | 2.56 ± 0.87 ^{ab} |
| 90 | 92.68 ± 2.31 ^{ab} | 2.14 ± 0.65 ^b | 4.01 ± 0.76 ^{ab} | 1.16 ± 0.57 ^b |

Note: ^a – the validity criterion $p \leq 0.05$ when compared with the previous period when comparing the same cell type in the second group, ^b – the validity criterion $p \leq 0.05$ when compared with the same period of time of the same cell type between the groups.

tissues, with some elevation areas. Inside the capsules, not all endoprosthesis threads are separated by connective tissue bridles, located in the form of “bags” in large cavities (Fig. 5A). However, already at this stage of the study, there are capsules that completely separate individual threads of the endoprosthesis.

By the 30th day, the capsule walls thicken, made of connective tissue fibers; the cell infiltrate is scarce; the proportion of neutrophils decreases compared to the 10th day up to three times (5.61%); the ratio of lymphocytes to macrophages changes towards the predominance of lymphocytes (8.52%). Along the inner layer of the capsule walls, multi-nuclear macrophages and mast cells are detected. All endoprosthesis threads are located in capsules (Fig. 5B), surrounded by fibrous septa, but there are focal ruptures. The walls of the capsules are still loosely connected to the surrounding tissues; there are small areas of their elevation. Loose connective tissue between capsules is rich in cells and vessels.

By the 60th day, single capsules appear with very thick and dense walls, consisting of isomorphic connective fibers that closely fit the endoprosthesis threads. Capsules are interconnected by dense bridles of fibrous connective tissue. The entire structure of the connective fabric frame is densely adherent to the surrounding tissue. However, there are still some areas of loose connective tissue rich in cells and vessels between the capsules and in the walls of individual capsules; there are capsules with thin

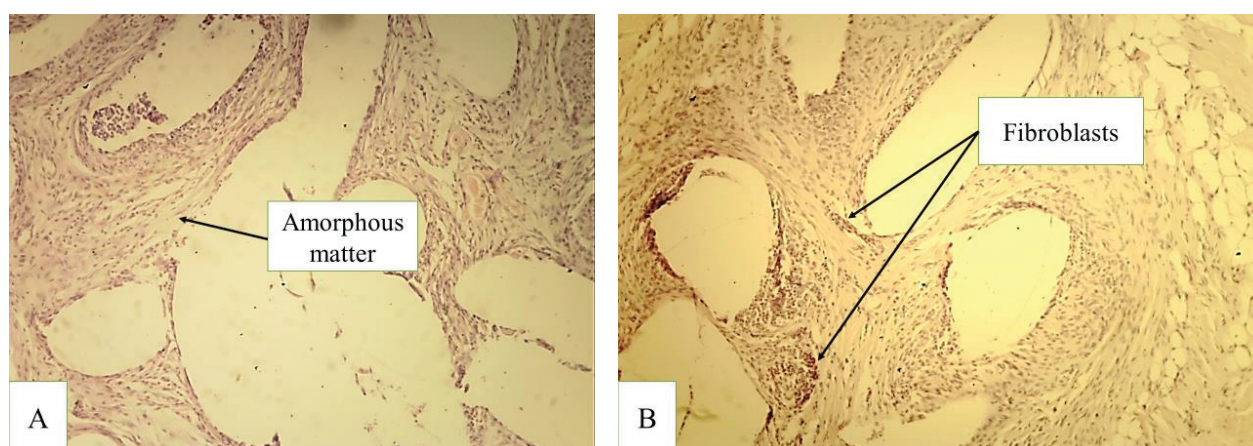


Figure 5. Microscopic picture at the site of Esphil endoprosthesis with a Solcoseryl coating on the 10th day (A) and 30th day (B). **Note:** Staining H+E. Light microscopy. X100.

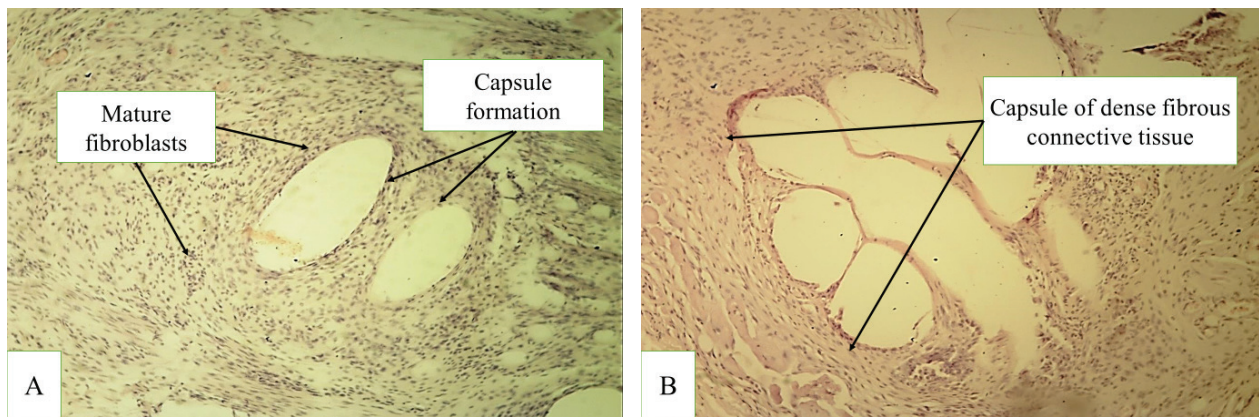


Figure 6. Microscopic picture at the site of Esphil endoprosthesis with a Solcoseryl coating on the 60th day (A) and 90th day (B). **Note:** staining H+E. Light microscopy. X100 (A) and X200 (B).

walls loosely enclosing the endoprosthesis threads, as well as small areas of rupture of fibrous septa dividing the threads, which indicates an ongoing process of organization in the field of the prosthesis. Small clusters of lymphocytes, macrophages, as well as single neutrophils are detected in the capsule walls (Fig. 6A). On their inside, there are giant cells of foreign bodies and mast cells. In the cell composition, there is a tendency to halve the number of neutrophils (2.56%), the proportions of macrophages and lymphocytes decrease as well, which reflects a decrease in the severity of the inflammatory reaction (Table 3).

By the 90th day, thick isomorphic connective fibers tightly enclose all the endoprosthesis threads (Fig. 6B). Inside the capsules with thick fibrous walls, all threads are separated by dense fibrous bridles. Fibrocytes with narrow elongated nuclei predominate along the inner side of the capsule walls, and multiple fibroblasts with oval volumetric nuclei are found towards the outside of the capsules. There are only isolated areas of loose newly formed connective tissue rich in cells and vessels. Fibroblasts (92.68%) prevail in the cell composition. The number of neutrophils decreases to 1.16%. This confirms the absence of acute inflammatory processes and the highest level of reparative processes.

Conclusion

In the cytological and histological analysis at the site of the Esphil endoprosthesis implantation without the use of coating, a consistent decrease in the exudative phase of the inflammatory reaction was observed in the control group. This was manifested primarily by a significant decrease in the number of neutrophils at the site of implantation from 18.4% on the 10th day to 6.2% by the 90th day. In addition, there was an 11.6% increase in the number of fibroblastic cells. However, no significant ($p \leq 0.05$) reduction in the lymphocyte and macrophage quantity at any stage of the experimental study was recorded.

A cytological analysis at the implantation site of the endoprosthesis with the applied collagen-stimulating coating was characterized by a significant ($p \leq 0.05$) decrease in the number of neutrophils by the 30th day of the experiment compared with the control group without using the coating. In the group using a Solcoseryl coating, when compared with the group of a Vitamin C coating, the number of white blood cells decreased significantly ($p \leq 0.05$) at all the stages of the experiment, indicating a faster exudative phase of inflammation.

In the group where the coating with Solcoseryl was used, a significantly ($p \leq 0.05$) less intense inflammatory reaction was noted at all the stages of the experiment. In this group, a persistent increase in the number of fibroblasts at all the experiment points ($p \leq 0.05$) was recorded: their number on the 10th day of the experiment was 15.5% more in the group where no coating was applied and 6% more in the group where the coating with Vitamin C was used. By the 90th day, this dependence remained, so the number of fibroblastic cells in the no-coating group was 22.64% less, and in the group with a Vitamin-C coating was 6.53% less. These changes indicate a significant biological inertness of the endoprosthesis with drug Solcoseryl, its best anti-inflammatory and collagen-stimulating effects.

Thus, during the experimental study of on-lay plastic modeling in the experimental animals with endoprostheses with and without various collagen-stimulating coating variants, faster inflammatory stages were found in the group where collagen-stimulating coatings were used. In addition, in the groups with coatings, there was a significant ($p \leq 0.05$) increase in the proliferation rate of fibroblastic cells to form a dense connective capsule around the endoprosthesis threads, while the paraprosthesis capsule in the control group animals was made up of loose connective tissue fibers. These changes indicate a higher strength of the paraprosthesis capsule in the coating groups and, accordingly, a better adaptation of the endoprosthesis in the tissues of the living organism.

References

- Aleksandrushkina NA, Grigorieva OA, Efimenko AY, Makarevich PI, Popov VS, Danilova NV, Mal'kov PG (2019) Cell sheets of mesenchymal stromal cells effectively stimulate healing of deep soft tissue defects. *Cell Technologies in Biology and Medicine* 167(1): 159–163. <https://doi.org/10.1007/s10517-019-04482-4> [PubMed]
- Ballard DH, Tappa K, Boyer CJ, Jammalamadaka U, Hemmanur K, Weisman JA, Alexander JS, Mills DK, Woodard PK (2019) Antibiotics in 3D-printed implants, instruments and materials: benefits, challenges and future directions. *Journal of 3D Printing in Medicine* 3(2): 1479–1481. <https://doi.org/10.2217/3dp-2019-0007> [PubMed] [PMC]
- Ermolov AS, Koroshvili VT, Blagovestnov DA (2018) Postoperative ventral hernia – unsolved issues of surgical tactics. *Surgery [Khirurgiya]* (10): 81–86. <https://doi.org/10.17116/hirurgia201810181> [in Russian]
- Graf S, Vasudavan S, Wilmes B (2018) CAD-CAM design and 3-dimensional printing of mini-implant retained orthodontic appliances. *American Journal of Orthodontics and Dentofacial Orthopedics* 154(6): 877–882. <https://doi.org/10.1016/j.ajodo.2018.07.013> [PubMed]
- Guessasma S, Nouri H, Roger F (2017) Microstructural and mechanical implications of microscaled assembly in droplet-based multi-material additive manufacturing. *Polymers* 9(8): 372. <https://doi.org/10.3390/polym9080372>
- Hamidian Jahromi A, Ballard DH, Griffen FD (2020) Mesh sprayer device with liquefied mesh delivery system: Proposed alternative for currently available meshes in hernia repair and supplement to abdominal closure. *Clinics in Surgery* 5: 2752. [PubMed] [PMC]
- Ivanov SV, Ivanov IS, Ob'edkov EG, Popova LP (2020) Determination of clinical efficiency of deproteinized dialysate from blood of vealers after endoprosthetics in patients with ventral hernias. *I.P. Pavlov Russian Medical Biological Herald [Rossiiskii Mediko-Biologicheskii Vestnik Imeni Akademika I.P. Pavlova]* 28(3): 323–333. <https://doi.org/10.23888/PAVLOVJ2020283323-333> [in Russian]
- Laronda MM, Rutz AL, Xiao S, Whelan KA, Duncan FE, Roth EW, Woodruff TK, Shah RN (2017) A bioprosthetic ovary created using 3D printed microporous scaffolds restores ovarian function in sterilized mice. *Nature Communications* 8(1): 15261. <https://doi.org/10.1038/ncomms15261> [PubMed] [PMC]
- Lazarenko VA, Ivanov SV, Ivanov IS, Parfenov IP, Goryainova GN, Tsukanov AV, Ivanova IA, Ob'edkov EG (2016) Morphological changes in the area of implanting “PARIETENE PROGRIP” endoprosthesis as a result of using SOLCOSERYL. *Kursk Scientific and Practical Bulletin “Man and Health” [Kurskii Nauchno-Prakticheskii Vestnik “Chelovek i Ego Zdorov’e”]* 3: 74–80. <https://doi.org/10.21626/vestnik/2016-3/12> [in Russian]
- Lazarenko VA, Ivanov SV, Ivanov IS, Ivanov AV, Tsukanov AV, Tarabrin DV, Kulabukhov AS, Tarabrina OV (2019) Comparative analysis of the effect of vitamin C and potassium orotate on the morphological picture during the implantation of a hernia mesh in an experiment. *Kursk Scientific and Practical Bulletin “Man and Health” [Kurskii Nauchno-Prakticheskii Vestnik “Chelovek i Ego Zdorov’e”]* 1: 33–40. <https://doi.org/10.21626/vestnik/2019-1/04> [in Russian]
- Ob'edkov EG, Ivanov SV, Ivanov IS, Zhabin SN, Ushanov AA (2019) Research of the indicators of biosocompatibility of a new sample of hernioendoprothesis when jointly used with deproteinized dialysate from blood of vealers. *Contemporary Problems of Science and Education [Sovremennye Problemy Nauki i Obrazovaniya]* 6: 156. [in Russian]
- Register of Medicines of Russia (2021a) Directory system “Register of Medicines of Russia” [electronic resource], Solcoseryl. [access mode:] https://www.rlsnet.ru/tn_index_id_2943.htm [call date: 25.04.2021]
- Register of Medicines of Russia (2021b) Directory system “Register of Medicines of Russia” [electronic resource], Vitamin C. [access mode:] https://www.rlsnet.ru/tn_index_id_523.htm [call date: 25.04.2021]
- Stepenko YV, Soldatov VO, Zatolokina MA, Mayorova AV, Sysuev BB, Demidenko AN, Ivahno EN, Sarycheva MV, Pokrovskiy MV (2019) Stimulation of reparation in a linear wound model in rats by Bischofit gel. *Pharmacy and Pharmacology [Farmatsiya i Farmakologiya]* 7(1): 42–52. <https://doi.org/10.19163/2307-9266-2019-7-1-42-5>
- Sukovatykh BS, Valuiskaya NM, Pashkov VM, Alimemko OV, Grigoryan AY (2016) Indications and choice of technology for polymeric materials implantation in the abdominal wall for prevention and treatment of postoperative ventral hernias. *Bulletin of Siberian Medicine [Byulleten' Sibirskoj Mediciny]* 15(1): 89–97. <https://doi.org/10.20538/1682-0363-2016-1-89-97> [in Russian]
- Tappa K, Jammalamadaka U (2018) Novel biomaterials used in medical 3D printing techniques. *Journal of Functional Biomaterials* 9(1): 1–16. <https://doi.org/10.3390/jfb9010017> [PubMed] [PMC]
- Tappa K, Jammalamadaka U, Ballard DH, Bruno T, Israel MR, Vemula H, Meacham JM, Mills DK, Woodard PK, Weisman JA (2017) Medication eluting devices for the field of OBGYN (MEDOBYN): 3D printed biodegradable hormone eluting constructs; a proof of concept study. *PLoS ONE* 12: e0182929. <https://doi.org/10.1371/journal.pone.0182929> [PubMed] [PMC]

Author contributions

- **Victor A. Lazarenko**, Rector of Kursk State Medical University, professor, Dr. habil. of Medical Sciences, Department of Surgical Diseases of Faculty of Postgraduate Education (FPE), Kursk State Medical University of the Ministry of Health of the Russian Federation, e-mail: azaroks@mail.ru, **ORCID ID** <http://orcid.org/0000-0002-2069-7701>. Concept and design of research, editing.
- **Sergey V. Ivanov**, Dr. habil. of Medical Sciences, Professor, Department of Surgical Diseases №1, Kursk State Medical University of the Ministry of Health of the Russian Federation, e-mail: IvanovSV@kursksmu.net, **ORCID ID** <http://orcid.org/0000-0001-7540-5748>. Concept and design of research, writing the text of the article and editing.

- **Tatyana A. Pankrusheva**, Doctor of Pharmaceutical Sciences, Professor of the Department of Pharmaceutical Technology, Kursk State Medical University of the Ministry of Health of the Russian Federation, e-mail: pankrushevata@kursksmu.net, **ORCID ID** <http://orcid.org/0000-0002-8288-4625>. Concept and design of research, editing the manuscript.
- **Ilya S. Ivanov**, Dr. habil. of Medical Sciences, Associate Professor, Department of Surgical Diseases №1, Kursk State Medical University of the Ministry of Health of the Russian Federation, e-mail: ivanov.is@mail.ru, **ORCID ID** <http://orcid.org/0000-0003-4408-961X>. Concept and design of research.
- **Galina N. Goryainova**, Ph.D., Associate Professor of the Department of Pathological Anatomy, Kursk State Medical University of the Ministry of Health of the Russian Federation, e-mail: lewis77@yandex.ru, **ORCID ID** <http://orcid.org/0000-0001-8856-0616>. Histological material description.
- **Evgeny G. Ob'edkov**, Ph.D., assistant of the Department of Surgical Diseases №1, Kursk State Medical University of the Ministry of Health of the Russian Federation, e-mail: cinnamonkla@yandex.ru, **ORCID ID** <http://orcid.org/0000-0003-0566-1476>. Collecting and processing the material, statistical processing, and writing the text of the manuscript.
- **Lyubov A. Kopteva**, student of the 5th year of the medical faculty of Kursk State Medical University of the Ministry of Health of the Russian Federation, e-mail: koptevatula@gmail.com, **ORCID ID** <http://orcid.org/0000-0002-3446-5362>. Collecting and processing the material, statistical processing, writing the text of the manuscript.
- **Marina S. Chekmareva**, PhD in Pharmaceutical Sciences, Associate Professor of the Department of pharmaceutical technology, Kursk State Medical University of the Ministry of Health of the Russian Federation. e-mail: chekmarevams@kursksmu.net, **ORCID ID** <http://orcid.org/0000-0002-1693-1892>. Collecting and processing the material.
- **Inna A. Ivanova**, Ph.D, Associate Professor of the Department of Clinical Immunology, Allergology and Phthisi-pulmonology, Kursk State Medical University of the Ministry of Health of the Russian Federation, e-mail: ia.ivanova@mail.ru, **ORCID ID** <http://orcid.org/0000-0002-7331-6255>. Collecting and processing the material.
- **Natalya Ju. Ob'edkova**, Assistant of the Department of Polyclinic Therapy and General Medical Practice (GMP), Kursk State Medical University of the Ministry of Health of the Russian Federation, e-mail: lewis77@yandex.ru, **ORCID ID** <http://orcid.org/0000-0003-2072-5511>. Collecting and processing the material.