



# Molecular and cellular mechanisms of acute cytotoxic liver damage as potential biological targets for magnesium-containing cell-protective drug

Marina O. Dudina<sup>1</sup>, Irina R. Suslova<sup>1</sup>, Mariya S. Khalzova<sup>1</sup>, Juliya V. Dergunova<sup>1</sup>, Evgeniya A. Kogan<sup>2</sup>, Dmitry A. Roshchin<sup>3</sup>, Elena A. Samyshina<sup>1</sup>, Mikhail A. Morozov<sup>1</sup>, Sergey S. Dydykin<sup>2</sup>

1 National Research Ogarev Mordovia State University, 68 Bolshevistskaya St., Saransk 430005, Russian Federation

2 Sechenov First Moscow State Medical University, 8 Trubetskaya St., Bldg. 2 Moscow 119991, Russian Federation

3 Federal State Budget Institution National Medical Research Radiology Center of the Ministry of Healthcare of the Russian Federation, 3 2<sup>nd</sup> Botkinski Drive Moscow 125284, Russian Federation

Corresponding author: Marina O. Dudina (a5pfvsis@yandex.ru)

Academic editor: Oleg Gudyrev ♦ Received 13 September 2018 ♦ Accepted 13 September 2018 ♦ Published 22 October 2018

**Citation:** Dudina MO, Suslova IS, Khalzova MS, Dergunova JV, Kogan EA, Roshchin DA, Samyshina EA, Morozov MA, Dydykin SS (2018) Molecular and cellular mechanisms of acute cytotoxic liver damage as potential biological targets for magnesium-containing cell-protective drug. Research Results in Pharmacology 4(3): 9–15. <https://doi.org/10.3897/rrpharmacology.4.29754>

## Abstract

**Introduction.** Many anti-tumor drugs have a high potential for toxic damage to liver cells, which makes it necessary to identify molecular mechanisms of the development of the negative impact of drugs on the liver and to develop effective methods for preventing and correcting this adverse effect.

**Materials and methods.** The study was performed on 30 nonlinear white rats of both sexes weighing 180–220 g, divided into 3 equal groups (n = 10 in each): intact control, control with liver pathology and experimental group of rats receiving the test substance LBK-527 at a dose of 100 mg/kg/day intragastrically one hour before the administration of a hepatotoxic cytarabine. In the animals of the latter two groups, acute drug-induced hepatitis was simulated by intravenous administration of 2 g/m<sup>2</sup> cytarabine in physiological saline for 5 days. Liver pathomorphology was studied on specimens stained with hematoxylin and eosin, Sudan III and by Van Gieson; a semi-quantitative method for assessing the depth of inflammatory and dystrophic organ damage was used. In the blood plasma, the activity of ASAT, ALAT, GGTP, and APF was determined. Tissue concentrations of TNF-alpha, IL-10 and HGF were determined by quantitative ELISA. Expression of Bcl-2 and Ki-67 was studied by immunohistochemistry. The proliferation index was calculated.

**Results and discussion.** Daily administration of LBK-527 for 5 days restrains the depth of cytarabine-induced pathomorphological changes in the liver, reduces the prevalence of the dystrophic and inflammatory process, increases the anti-inflammatory and regenerative potential of the hepatic parenchyma, inhibits the programmed death of hepatocytes and reduces the activity of cytolytic and cholestatic syndromes.

**Conclusion.** Magnesium-containing cell-protective substance LBK-527 protects liver from cytarabine-induced injury.

## Keywords

alcoholic hepatitis, liver, cytokines, LBK-527, cytarabine, Ki-67, Bcl-2, hepatocytes.

## Introduction

Diagnosis of drug damage to the liver is often difficult due to the fact that the hepatotoxic effect of many drugs can mimic other organ diseases (Bénichou 1990). In addition, there are neither specific biological – histological or biochemical – markers of drug-induced hepatotoxicity, nor are there reliable methods for identifying a hepatotoxicant in the vast majority of cases (Mori et al. 1997, Remesh 2012). In the case of antitumor chemotherapy, the situation is complicated by the severity of the underlying disease, which under certain circumstances can also cause impairment of the function and morphology of the liver (Larroquette et al. 1986). Against the background of the administration of specific anti-tumor agents, slight hyperenzymemia is generally ignored by clinicians, whereas the leading principles at the appearance of signs of hepatotoxic effect of drugs are early diagnosis and immediate discontinuation of the drug in the body (Farrow et al. 1997, Twelves et al. 1998).

At the same time, most anti-tumor drugs have a high potential for damage to liver structures: hepatocytes, endothelial cells of sinusoids, and macrophage elements colonizing the organ (DeLeve 1996). All this makes it necessary to identify molecular mechanisms for the development of the negative impact of drugs on the liver and to develop effective methods for preventing and correcting this adverse effect.

### Study goal

To validate the points of application of the hepatoprotective effect of the magnesium-containing 2-aminoethanesulfonic acid derivative, based on the analysis of the key molecular and cellular processes underlying the development of acute drug damage to the rat liver with an anti-tumor drug cytarabine.

## Materials and methods

### Experimental animals

The experiments were performed on 30 white nonlinear rats of both sexes with a baseline weight of 180–220 g, obtained from Andreevka Branch of the Scientific Center for Biological and Medical Technologies, in compliance with the requirements of order No. 199H of the Ministry of Healthcare of Russia dated 01.04.2016 “On Approval of the Rules of Good Laboratory Practice”, based on the principles of humane treatment of experimental animals in accordance with the European Convention for the Protection of Vertebrates. The protocols of the experiments passed an ethical review at a meeting of the Local Ethics Committee of Ogarev National Research Mordovia State University (October 21, 2017, Minutes No. 10). The animals were divided into 3 experimental groups

of 5 females and 5 males in each: 1<sup>st</sup> – intact animals; 2<sup>nd</sup> – control with cytarabine-induced acute drug damage (CIADD); 3<sup>rd</sup> – animals with CIADD treated with the tested substance (LBK-527).

### CIADD modeling method

Acute drug damage to the liver was formed by intravenous administration of cytarabine at a dose of 2 g/m<sup>2</sup> of the animal’s body surface in 3 ml physiological saline to the rats of the 2<sup>nd</sup> and 3<sup>rd</sup> groups for 5 days (Singh et al. 2012, Liu et al. 2013, Lakshmi et al. 2014). Cytosar 100 mg, lyophilizate for solution for intravenous injections (manufactured by Pfizer Inc., Germany), was used. The same amount of physiological saline was administered intravenously to the intact rats daily. On the sixth day, the rats were sacrificed by decapitation under ether anesthesia.

### Biochemistry

The activity of aspartate aminotransferase (ASAT), alanine aminotransferase (ALAT), gamma-glutamyl transpeptidase (GGTP), alkaline phosphatase (APF) was determined in the blood serum using a FUJI DRI CHEM 4000i veterinary biochemical analyzer (Japan) and using a FUJIFILM standard diagnostic kit (Japan).

### Morphological examination

The liver was removed from the animals, and after being weighed and visually examined, it was divided into four approximately equal parts. One organ fragment was fixed in 10% neutral formalin solution; after being drained, it was embedded into paraffin and used for histological examination after having the sections stained with hematoxylin and eosin, and special Van-Gieson staining. To do this, after deparaffinisation, using a sledge microtome, 5–6 µm thick slices were made and stained with dyes by standard techniques. The second, non-fixed, fragment of the liver was frozen and then stained with an alkaline solution of Sudan III. Morphometry of the liver sections was analyzed using the Image Scope Color and cellSens Standard image analysis software (Russia). For this purpose, photomicrographs of random visual fields of histological preparations were taken by OLYMPUS XCOLYMPUS XC-30 digital camera based on OLYMPUS BX51 microscope (Japan) with eyepiece magnification SWHx10 and UPLanFL x200, x400 lenses (at least 10 fields of vision in each histological section). On haematoxylin and eosin sections, a semi-quantitative analysis of the CIADD severity was used in terms of the area of hepatic parenchyma affected by the inflammatory-dystrophic process (Zhao et al. 2017). Using specimens stained with Sudan III, the percentage of hepatocytes with steatosis phenomena was determined, as well as the area of hepatocyte cytoplasm covered with fat drops.

### Immunohistochemistry

The third fragment of the liver was frozen, then 3–4 μm thick cryostat sections were used for immunohistochemistry (IHC) with streptavidin-biotin amplification method. Rabbit Polyclonal IgG Bcl-2 Antibodies (C21) (Santa Cruz, USA) were applied to apoptosis regulator Bcl-2, and Mouse Monoclonal Anti-Ki-67 ((Clone M11) (K-2), IgG1, Novo Castra, United Kingdom) – to Ki-67 proliferation factor. Mayer’s hematoxylin was used for the contrast staining of the nuclei. Analysis of the IHC reaction was carried out in 6 fields of vision (3 fields from the central lobular and 3 ones from the peripheral parts of the hepatic lobule), with ×400 magnification. A proportion of Bcl-2-positive cells was determined; the proliferation index was calculated to evaluate the response to Ki-67.

### ELISA test

TNF-alpha, hepatocyte growth factor (HGF), and IL-10 concentration in liver tissue was determined in the homogenate of the fourth liver fragment by means of quantitative ELISA and a research kit of antibodies (Cusabio Biotech Co., LTD., USA) on a StatFax 4200 automatic reader (USA).

### Studied pharmacological agent

The magnesium salt of 2-aminoethanesulfonic acid (the code of the developer’s institution – LBK-527) was studied as a substance (All-Union Research Center for Biological Active Substances Safety, Russia). The tested substance was daily administered to the animals intragastrically, 1 hour prior to the administration of cytarabine at a dose of 100 mg/kg/day for 5 days. The intact animals and the rats with CIADD (groups 1 and 2) from the control group were administered drinking water in a similar regime and amount throughout the experiment.

### Statistical data processing

The data were statistically processed by parametric and nonparametric methods, with a 5% level of significance by means of the BioStat software (Glantz 2012).

## Results and discussion

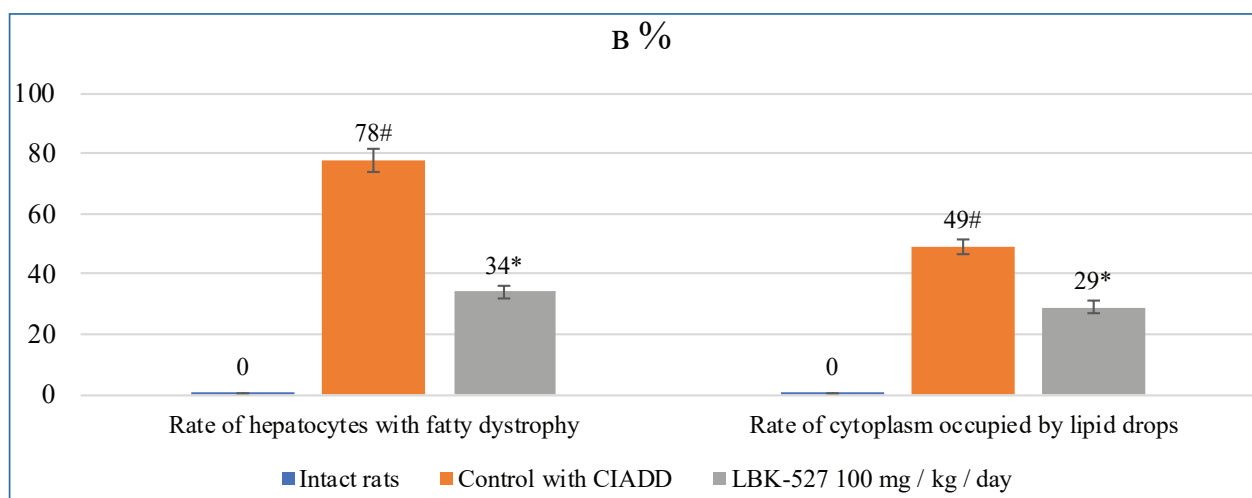
Daily intravenous administration of 2 g/m<sup>2</sup> of the animal’s body surface area of cytarabine in rats for 5 days morphologically manifested by an increase in absolute and relative liver mass and hepatocyte hypertrophy, structural damage of the organ, vacuolization of the cytoplasm of hepatocytes, karyopcnosis and karyolysis, the appearance of necrosis, leuco- and lymphohistiocytic infiltration, steatosis and the initial signs of fibrosis. The use of a semi-quantitative method for assessing the prevalence of the inflammatory-dystrophic process made it possible to assess the depth of the organ pathological changes, characterized by involving more than 66% of the liver parenchyma into the pathological process (Table 1).

Intragastric administration of magnesium-containing compound of 2-aminoethanesulfonic acid at a dose of 100 mg/kg/day to rats receiving cytarabine inhibited the formation of a pattern of acute toxic liver damage, which manifested itself in normalizing the structural organizati-

**Table 1.** Semi-quantitative Characteristics of Inflammatory-dystrophic Liver Reaction of Rats with CIADD under the Influence of LBK-527 According to Zhao et al. 2017.

Group of animals	0	+	++	+++
Intact rats	10	0	0	0
Control with CIADD	0*	0	3	7*
CIADD, LBK-527 100 mg/kg/day	0*	7 <sup>^</sup> *	3	0 <sup>^</sup>

Note: \* – p<0,05 in comparison with intact rats; <sup>^</sup> – p<0,05 in comparison with control CIADD (Fisher’s exact test)



**Figure 1.** Morphometric features of fatty dystrophy of rats with CIADD treated with LBK-527. Note: # – p<0,05 in comparison with intact rats; \* – p<0,05 in comparison with intact rats and control with CIADD (ANOVA, Dannet criterion)

on of the hepatic parenchyma, reducing the depth of the inflammatory and dystrophic process (Table 1), and absence of signs of expansion of connective tissue elements.

The severity of steatosis, quantitatively characterized by the proportion of hepatocytes with fatty dystrophy and the area of cytoplasm of the liver parenchyma cells under fatty drops significantly decreased when compared to those in the animals in the control group (Figure 1).

The result of the histoprotective effect of LBK-527 compound was a decrease in the plasma concentration of intracellular enzymes (ASAT, ALAT and GGTP) when compared to that in the animals of the control with CIADD, and a decrease in the intrahepatic cholestasis (Table 2).

Five days after the course of daily intravenous injection of cytarabine solution to the animals, an increase in TNF-alpha tissue concentration by more than two and a half times – on average to 26.2 pg/ml ( $p = 0.001$  when compared to the intact animals) against the background of almost a four-fold decrease in the level of anti-inflammatory cytokine-IL-10 to 3.8 pg/ml ( $p = 0.001$  when compared with intact animals) – was observed. At the same time, a proportional (four-fold) increase in tissue concentration of hepatocyte growth factor (HGF) – up to 0.61 pg/ml ( $p = 0.001$  when compared to the intact animals) was observed, which was regarded as a compensatory reaction aimed to form hypertrophy of hepatocytes and their functional replacement in response to cytarabine-induced death of hepatocytes.

LBK-527 at a dose of 100 mg/kg/day also had a significant effect on tissue concentrations of cytokines in the liver of animals with emerging acute drug hepatitis (Table 2). Tissue concentration of pro-inflammatory cytokine TNF-alpha was restored to reach the values observed in the liver of intact animals; the level of IL-10 was 50% higher than that in the intact group. The tissue level of HGF against the background of administration of the compound remained high.

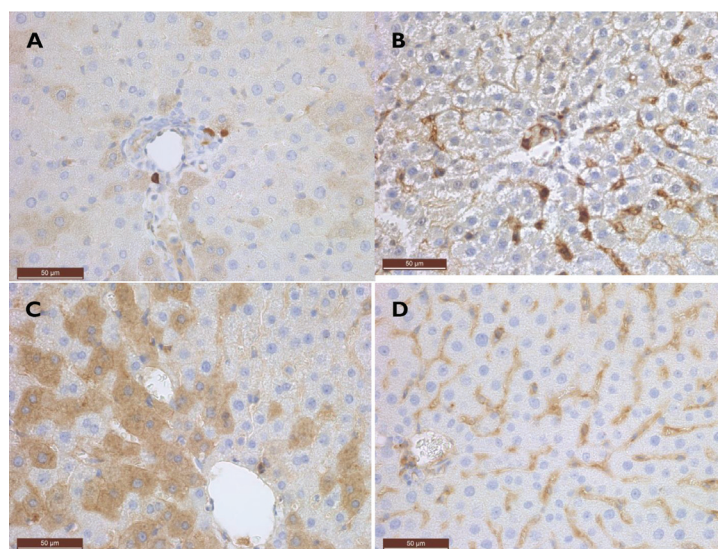
In the intact animals, a low expression of the apoptosis regulatory factor was observed, as judged from the low intensity of brown staining of the hepatocyte cytoplasm (Fig. 2a). Against the background of the formation of acute cytarabine-induced damage to the hepatic parenchyma, an increased expression of Bcl-2 in the animals' liver microscopic specimens was observed (Fig. 2b), which may indicate a compensatory activation of tissue protective mechanisms against the background of emerging necrosis and an inflammatory response: a moderate immunohistochemical reaction was registered predominantly in hepatocytes of the central parts of the lobule. The antiapoptotic effect of LBK-527 at a dose of 100 mg/kg/day was evident by highly intensive staining of the cytoplasm of hepatocytes, mainly in the central part of the liver lobule (Fig. 2C, D).

Ki-67 is a highly sensitive marker of cell proliferation (Pujani et al. 2011). The liver parenchyma of intact rats is

**Table 2.** The Values of Some Biochemical Parameters of Liver Function and Tissue Concentration of Cytokines (M±SD) in Rats with CIADD Treated with LBK-527.

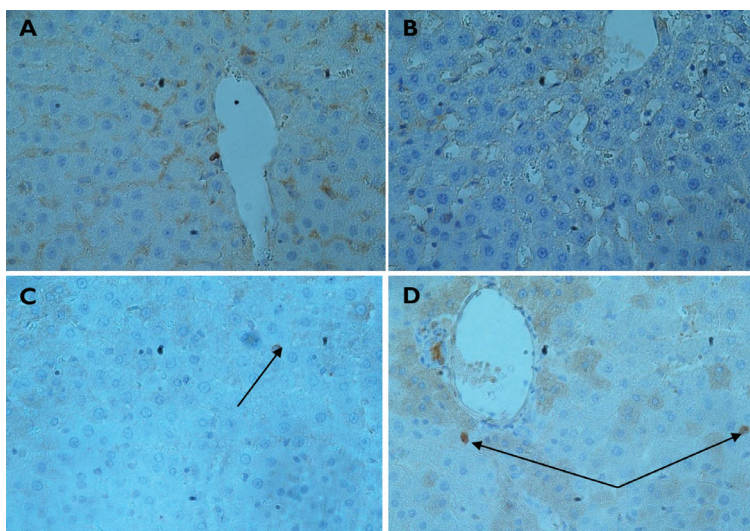
Group	ASAT U/l	ALAT U/l	APF U/l	GGTP U/l	FNO-alpha pg/ml	IL-10 pg/ml	HGF pg/ml
Intact Rats	13.8±2.3	11.3±1.4	219.5±8.5	1.1±0.3	10.6±0.8	13.2±0.6	0.16±0.03
Control with CIADD	281.7±5.2*	69.1±2.2*	293.6±6.1*	7.1±0.7*	26.2±1.6*	3.8±0.4*	0.61±0.09*
CIADD, LBK-527 100 mg/kg/day	119.6±3.1 <sup>B</sup> *	47.2±3.6 <sup>B</sup> *	211.0±3.4 <sup>B</sup>	2.2±0.5 <sup>B</sup>	13.0±1.3 <sup>B</sup>	19.1±1.5 <sup>B</sup> *	0.84±0.11 <sup>B</sup>

Note: \* –  $p < 0.05$  when compared to intact rats; <sup>B</sup> –  $p < 0.05$  when compared to control with CIADD (ANOVA, Dannel criterion)

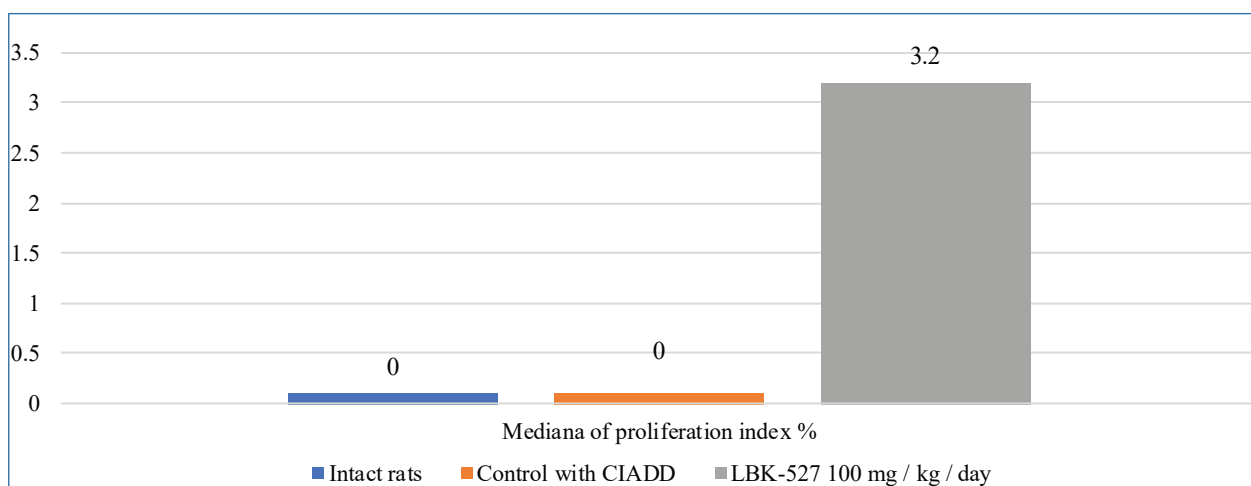


**Figure 2.** IHC study of liver. Bcl-2 staining. ×400: **A** intact rats; **B** control with CIADD; rats with CIADD treated with LBK-527, 100 mg/kg/day; **C** center of lobule; **D** the lobule periphery





**Figure 3.** Ki-67 expression in rat’s hepatocyte nuclei (indicated by the arrows, x 400): **A** intact rat’s liver; **B** liver of rat with CIADD; liver of rat with CIADD treated with LBK-527, 100 mg/kg/day **C** lobule periphery; **D** center of the lobule.



**Figure 4.** Proliferation index value (according to Ki-67 expression) in liver of rats with CIADD

expressed by resting non-proliferating hepatocytes (Fig. 3a). In the liver of the animals with CIADD, expression of Ki-67 was observed neither in the centrolobular nor in the peripheral parts of the liver lobule (Fig. 3b). The pharmacological effect of LBK-527 was accompanied by an increase in the expression of the proliferation marker (Figure 3c, d), as evidenced by an increase in the proliferation index (Fig. 4).

Thus, intravenous administration of toxic doses of cytarabine induces acute drug liver damage in rats characterized by the development of necrosis, the inflammatory-dystrophic reaction, activation of apoptosis of hepatocytes, hypertrophy of parenchymal cells, cytolysis and cholestasis. Prophylactic intragastric administration to animals of a magnesium-containing compound of 2-aminoethanesulfonic acid at a higher therapeutic dose of 100 mg/kg daily for 5 days makes it possible to restrain the hepatotoxicity of cytarabine and to reduce the depth of damage to the liver of animals.

## Conclusions

1. Daily intragastric LBK-527 administration leads to the preservation of the microstructure of the liver: the lobular morphology and the beam structure of the organ parenchyma, the prevention of hepatic cell death, and a decrease in the intensity of the inflammatory-dystrophic process mainly of the lobular center.
2. The liver-protective effect of substance LBK-527 against the background of the development of acute cytarabine-induced liver damage is manifested in the prevention of anticancer drug-mediated cytolysis and cholestasis.
3. LBK-527 reduces the tissue concentration of TNF-alpha, restores the level of anti-inflammatory IL-10 to the level of that in the intact animals, increases the expression of the anti-apoptotic factor Bcl-2 and activates the proliferation potential of hepatocytes (Ki-67 level), mainly in the periphery of the hepatic lobule in the animals receiving toxic doses of antitumor anti-metabolite cytarabine.

## Acknowledgements

The authors are grateful to Professor S.Ya. Skachilova for substance LBK-527 provided for the study.

The study was partly supported by The Russian Foundation for Promotion of Innovation (Project No. 10997ГҮ/2016).

## References

- Bénichou C (1990) Criteria of drug-induced liver disorders. Report of an international consensus meeting. *Journal of Hepatology* 11(2): 272–276. [https://doi.org/10.1016/0168-8278\(90\)90124-a](https://doi.org/10.1016/0168-8278(90)90124-a) [PubMed]
- DeLeve LD (1996) Cellular target of cyclophosphamide toxicity in the murine liver: role of glutathione and site of metabolic activation. *Hepatology* 24(4): 830–837. <https://doi.org/10.1053/jhep.1996.v24.pm0008855185> [PubMed]
- Farrow AC, Buchanan GR, Zwiener RJ et al. (1997) Serum aminotransferase elevation during and following treatment of childhood acute lymphoblastic leukemia. *Journal of Clinical Oncology: Official Journal of the American Society of Clinical Oncology* 15(4): 1560–1566. <https://doi.org/10.1200/jco.1997.15.4.1560> [PubMed]
- Glantz SA (2012) *Primer of biostatistics (7<sup>th</sup> edn)*. The McGraw-Hill Companies, Inc., 320 p.
- Remesh A (2012) Toxicities of anticancer drugs and its management. *International Journal of Basic and Clinical Pharmacology* 1(1): 1–12. <https://doi.org/10.5455/2319-2003.ijbcp000812>
- Lakshmi BVS, Sudhakar M, Shashank P (2014) Protective role of hydro alcoholic extract of *Vitis vinifera* against Adriamycin induced cardiac, renal and hepatic toxicities. *International Journal of Pharmaceutical Sciences Review and Research* 3(5): 13–19.
- Larroquette CA, Hortobagyi GN, Buzdar AU, Holmes FA (1986) Sub-clinical hepatic toxicity during combination chemotherapy for breast cancer. *Journal of the American Medical Association* 256(21): 2988–2990. <https://doi.org/10.1001/jama.1986.03380210084030> [PubMed]
- Liu Y, Meyer C, Xu C, et al. (2013) Animal models of chronic liver diseases. *American Journal of Physiology. Gastrointestinal and Liver Physiology* 304(5): 449–468. <https://doi.org/10.1152/ajpgi.00199.2012> [PubMed]
- Mori T, Sugita K, Suzuki T et al. (1997) Histopathologic features of the biopsied liver at onset of childhood B-precursor acute lymphoblastic leukemia presenting as severe jaundice. *Journal of Pediatric Gastroenterology and Nutrition* 25(3): 354–357. <https://doi.org/10.1097/00005176-199709000-00021> [PubMed]
- Pujani M, Arora B, Pujani M, et al. (2011) Role of Ki-67 as a proliferative marker in lesions of thyroid. *Indian Journal of Cancer* 48(3): 304–307. <https://doi.org/10.4103/0019-509x.64727>
- Singh R, Kumar S, Rana AC, Sharma N (2012) Different model of hepatotoxicity and related liver diseases: a review. *Int. Res. J. Pharm.* 3: 86–94. [Google Scholar]
- Twelves CJ, Dobbs NA, Gillies HC, et al. (1998) Doxorubicin pharmacokinetics: the effect of abnormal liver biochemistry tests. *Cancer Chemother Pharmacol* 42(3): 229–234. <https://doi.org/10.1007/s002800050809> [PubMed]
- Zhao J, Zhang Y, Wan Y, Hu H, Hong Z (2017) Pien Tze Huang Gan Bao attenuates carbon tetrachloride-induced hepatocyte apoptosis in rats, associated with suppression of p53 activation and oxidative stress. *Molecular Medicine Reports* 16(3): 2611–2619. <https://doi.org/10.3892/mmr.2017.6936>

## Author contributions

- **Marina O. Dudina**, postgraduate student, The Medical Institute, National Research Ogarev Mordovia State University, 68 Bolshevistskaya St., Saransk 430005 Russia, [a5pfvvis@yandex.ru](mailto:a5pfvvis@yandex.ru). The author conducted experiments in animals.
- **Irina R. Suslova**, postgraduate student, The Medical Institute, National Research Ogarev Mordovia State University, 68 Bolshevistskaya St., Saransk 430005 Russia, [irina.suslova1@inbox.ru](mailto:irina.suslova1@inbox.ru). The author performed biochemistry and ELISA.
- **Mariya S. Khalzova**, postgraduate student, The Medical Institute, National Research Ogarev Mordovia State University, 68 Bolshevistskaya St., Saransk 430005 Russia, [xalmas@mail.ru](mailto:xalmas@mail.ru). The author conducted experiments in animals as well as prepared the manuscript for publishing.
- **Juliya V. Dergunova**, postgraduate student, The Medical Institute, National Research Ogarev Mordovia State University, 68 Bolshevistskaya St., Saransk 430005 Russia, 430005, [yulya@rambler.ru](mailto:yulya@rambler.ru). The author conducted experiments in animals.
- **Evgeniya A. Kogan**, Doctor of Medical Sciences, Professor, Head of the Department of Pathology, Sechenov First Moscow State Medical University, 8 Trubetskaya St., Moscow 119991 Russia, [pyrk@yandex.ru](mailto:pyrk@yandex.ru). The author performed IHC examination and participated in the manuscript revision process.

- **Dmitry A. Roshchin**, Candidate of Medical Sciences, Head of the Department, National Medical Research Radiology Center, 3 2<sup>nd</sup> Botkinski Drive, Moscow 125284 Russia, [dr89031990702@gmail.com](mailto:dr89031990702@gmail.com). The author performed morphological examination.
- **Elena A. Samyshina**, Candidate of Medical Sciences, Senior research fellow, Novel Medication Research Center, National Research Ogarev Mordovia State University, 68 Bolshevistskaya St., Saransk 430005 Russia, [bds131@yandex.ru](mailto:bds131@yandex.ru). The author conducted experiments in animals and did the statistical data processing.
- **Mikhail A. Morozov**, sixth-year student, The Medical Institute, National Research Ogarev Mordovia State University, 68 Bolshevistskaya St., Saransk 430005 Russia, [m-i-s-h-e-l@mail.ru](mailto:m-i-s-h-e-l@mail.ru). The author conducted experiments in animals.
- **Sergey S. Dydykin**, Doctor of Medical Sciences, Professor, Head of the Department of Topography, Anatomy and Operative Surgery, Sechenov First Moscow State Medical University, 8 Trubetskaya St., Moscow 119991 Russia, [dydykin\\_ss@mail.ru](mailto:dydykin_ss@mail.ru). The author designed the study concept and ran the study.